

## ORIGINAL ARTICLE

# Topical versus interlesional mitomycin C in auricular keloids



Yasser Mandour\*, Hossam Bake, Esmael Mofty, Eman Ramadan, Mostafa Gomaa, Essam Akl, Ahmed Elrefae

Faculty of Medicine, Benha University, Benha, Egypt

Received 25 April 2020; accepted 18 June 2020

## KEYWORDS

Keloid;  
Auricle;  
Mitomycin;  
Topical

## Abstract

**Background:** The Keloid is an elevated fibrous scar that may extend beyond the borders of the original wound.

**Object:** To compare between topical and intralesional mitomycin C in the treatment of auricular keloids.

**Patients and methods:** Prospective randomized study in which 40 patients with auricular keloids were included. The patients were divided into 2 groups, Group I included 32 patients who underwent topical mitomycin C application after the surgical removal of the auricular keloids, while Group II included 8 cases who underwent intra-lesional injection of mitomycin C after surgical removal of the auricular keloids.

**Results:** The two groups showed no significant difference regarding patient or lesion criteria ( $p > .05$ ). VSS decreased significantly from 10.63 and 11.0 down to 1.38 and 3.0 after treatment in the topical and intra-lesional groups respectively ( $p < .001$ ). However, greater improvement and satisfaction was detected in the topical group.

**Conclusion:** Both topical and intra-lesional mitomycin C injection are effective methods in managing auricular keloids. However, better VSS scores and patient satisfaction are reported with topical administration.

© 2020 Sociedad Española de Otorrinolaringología y Cirugía de Cabeza y Cuello. Published by Elsevier España, S.L.U. All rights reserved.

## PALABRAS CLAVE

Queloides;  
Aurícula;  
Mitomicina;  
Tópico

## Mitomicina C tópica vs interlesional en queloides auriculares

### Resumen

**Antecedentes:** El queloides es una cicatriz fibrosa elevada que puede extenderse más allá de los límites de la herida original.

\* Corresponding author.

E-mail address: [ghader\\_massoud@yahoo.com](mailto:ghader_massoud@yahoo.com) (Y. Mandour).

**Objetivo** Comparar mitomicina C tópica frente a intralesional en el tratamiento de los queloides auriculares.

**Pacientes y métodos:** Estudio prospectivo aleatorio en el que se incluyó a 40 pacientes con queloides auriculares, que se dividieron en 2 grupos: el Grupo I incluyó 32 pacientes a quienes se aplicó mitomicina C tópica tras la resección quirúrgica de los queloides, y el Grupo II que incluyó 8 casos, a quienes se inyectó mitomicina C dentro de la lesión, tras la resección quirúrgica de los queloides auriculares.

**Resultados:** Los 2 grupos no reflejaron diferencia significativa en cuanto a criterios de pacientes o lesión ( $p > 0,05$ ). La escala de Vancouver (VSS) disminuyó significativamente de 10,63 y 11 a 1,38 y 3 tras el tratamiento en los grupos de aplicación tópica e intra-lesional, respectivamente ( $p < 0,001$ ). Sin embargo, se detectaron una mejora y satisfacción más altas en el grupo de aplicación tópica.

**Conclusión:** Las aplicaciones tópica e inyectada de mitomicina C son métodos efectivos para el tratamiento de queloides auriculares. Sin embargo, se reportaron mejores puntuaciones VSS y de satisfacción del paciente con la administración tópica.

© 2020 Sociedad Española de Otorrinolaringología y Cirugía de Cabeza y Cuello. Publicado por Elsevier España, S.L.U. Todos los derechos reservados.

## Introduction

Keloid is an elevated fibrous scar that may extend beyond the borders of the original wound, usually do not regress, and recur after the surgical excision. The term is related to the Greek word cheloides (crab's claw).<sup>1</sup> Development of keloids may take months or years to occur after injury. It is an abnormal healing responses to dermal injury, with excessive deposition of collagen tissue.<sup>2</sup>

Young Patients less than 30 years and Patients with dark skin are at high risk of keloids. High risk trauma may include burns, ear piercing and any factor that can prolong the wound healing. The most susceptible sites to have keloids are Sternal skin, shoulders, upper arms, earlobes, and cheeks.<sup>3</sup>

Keloids can extend into the surrounding normal tissue and do not regress so It may continue to evolve over time. The earlobes and the helix of the auricle are common sites for keloids formation after a trauma or ear piercing.<sup>4</sup>

Small single keloid can be treated by surgical excision with adjuvant therapy like steroid injections or by non-surgical treatment like (corticosteroid injections, cryotherapy, pulse dye laser and antitumor/immunosuppressive agents like 5-fluorouracil, bleomycin, imiquimod, retinoic acid and colchicine). The large or multiple keloids are difficult to be treated by radical surgical excision only but need multimodal therapies that aim to relieve symptoms.<sup>5</sup>

The mitomycin C is an antibiotic that inhibits cell division and prevents fibroblast proliferation, It can be used for treatment of keloids.<sup>6</sup>

Mitomycin C (MMC) is a natural antibiotic which was isolated in 1958 from the broth of *Streptomyces caespitosus* fermentation. It had anti tumour activity in preclinical animal screens. It is less toxic than other mitomycins.<sup>7</sup>

The Mitomycin-C can alkylate and cross-links DNA to inhibit the synthesis of protein and DNA. The Keloid fibroblasts with mitomycin-C treatment have decreased DNA

synthesis and decreased density compared with Keloid fibroblasts with buffered saline treatment. The Mitomycin-C inhibits fibroblast proliferation and decreases the fibrosis in the wounds that treated with its topical form, with no apparent side effects to skin incision sites.<sup>8</sup>

## Patients and methods

This was a prospective randomized study that was conducted over a period of one year, from June 2017 to May 2019, on 40 patients who were treated by local application of mitomycin C, either topical or intralesional, for auricular and postauricular keloids at ENT and Dermatology outpatient clinics of Benha University Hospitals, Local ethical committee approval of Benha University Hospitals and informed consent were taken before the onset of the study (Fig. 1).

The patients whose age ranged between 10 and 50 years were included in the study the duration of scars ranged between 6 and 18 months, but the patients with mitomycin hypersensitivity or other otological disorders were excluded in this study (Fig. 2).

The patients in this study were randomly divided into two groups; group I which included 32 patients who underwent topical application of mitomycin C, and group II which included 8 patients who underwent intralesional injection of the same drug (Fig. 3).

All patients were subjected to history taking and otological examination, photographs of the lesions were taken before treatment. In group I, the scars were shaved to the level of the skin under local anaesthesia. A wound-shaped cotton pledget was immersed in mitomycin that prepared with distilled water at a concentration of 1 mg/mL and placed over the wound for 3 min, then the wound covered by a simple dressing. In group II, the scars were shaved to the level of the skin under local anaesthesia, with intralesional mitomycin C (prepared with distilled water in a concentration of 1 mg/mL) was carried out (Fig. 4).

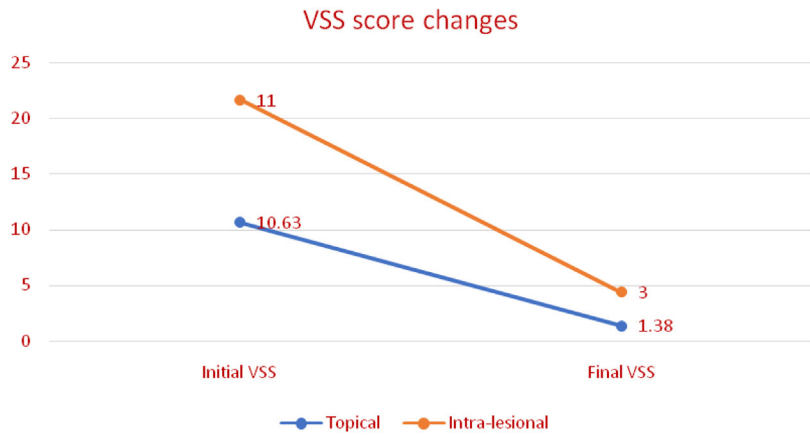


Figure 1 VSS changes after treatment in both study groups.

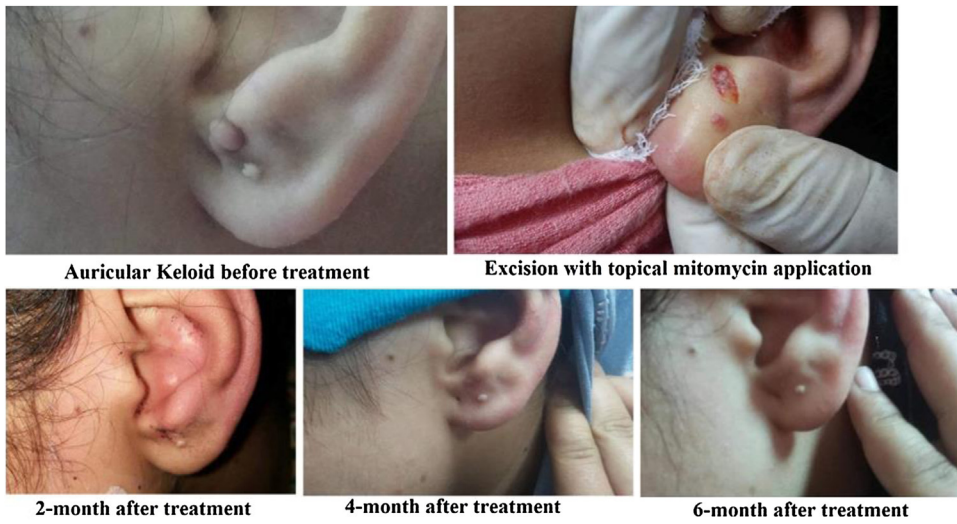

Figure 2 Female patient aged 17 years underwent excision and topical application of mitomycin C.

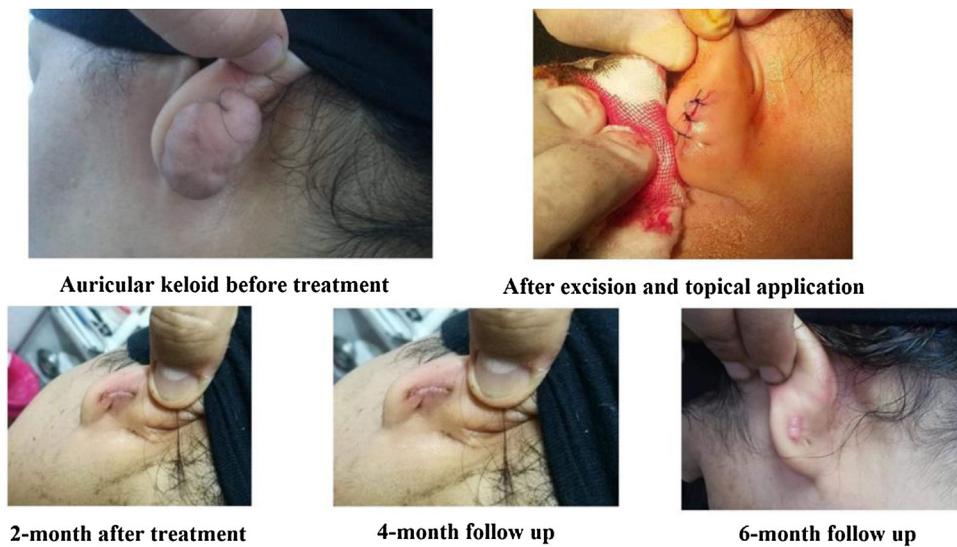
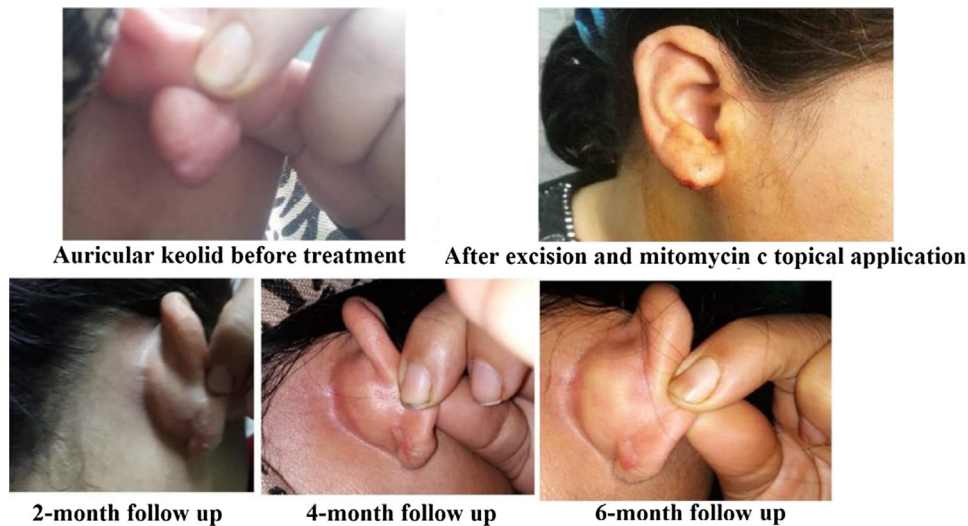
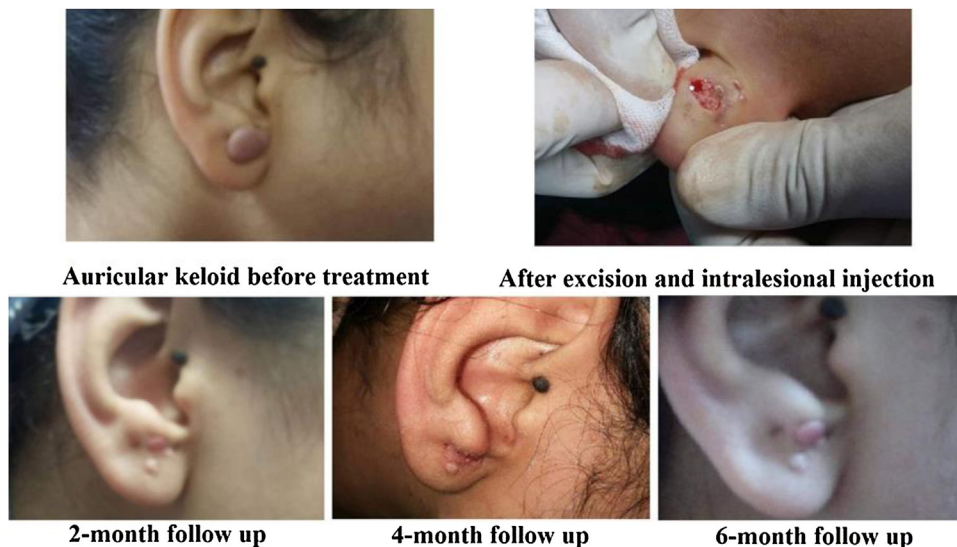


Figure 3 Female patient aged 45 years who presented with auricular keloid and underwent excision with topical mitomycin C application.



**Figure 4** Female patient aged 39 years who underwent local excision and topical mitomycin application for auricular keloids.



**Figure 5** Female patient aged 22 years who underwent excision and intralesional injection of mitomycin C for auricular keloid.

The patient satisfaction and the Vancouver Scars Scale (VSS) were recorded after 6 months. The Patient satisfaction was graded as disappointing, fair, good and excellent (Fig. 5).

The patients were followed up every month for 6 months after the start of treatment. A photograph was taken every 2month for a total of 6 months. At 6 months, a final photograph of the lesion was also taken. Local and systemic side effects were observed at each visit (Table 1).

### Statistical analysis

Data was entered and analyzed using Microsoft Excel software. Data were then imported into Statistical Package for the Social Sciences (SPSS 21.0, IBM/SPSS Inc., Chicago, IL) software for analysis. Baseline characteristics of the study population were presented as frequencies and percentages (%) or mean values and standard deviations (SD

(after testing of normality by Kolmogorov–Smirnov and Shapiro–Wilk’s tests) (Table 2).

For comparison of data, Chi-Square test (or Fisher’s exact test) was used to compare two independent groups of qualitative data and McNemar test was used to compare two related groups of qualitative data at different time points. For quantitative data, independent-Samples t-test and Mann–Whitney U test were used to compare two groups of parametric and non-parametric quantitative data respectively.  $p$  value  $< 0.05$  would be considered statistically significant (\*) while  $> 0.05$  statistically insignificant  $p$  value  $< 0.01$  would be considered highly significant (\*\*) in all analyses, Table 3.

### Results

The mean age in this study was 36.88 and 43.0 in the topical and intralesional groups respectively. A total of 12 males

**Table 1** Vancouver scars scale [5].

	Pigmentation	Vasculatity	Pilability	Height
0	Normal colour (closely resembles the colour of nearby skin)	Normal	Normal	Normal (flat)
1	Hypopigmentation	Pink (slight increase in local blood supply)	Supple (flexible with minimal resistance)	Less than 2 mm
2	Hyperpigmentation	Red (significant increase in local blood supply)	Yielding (giving way to pressure, offering moderated resistance, but does not behave as solid scar mass)	2–5 mm
3	-	Purple (excessive increase in local blood supply)	Firm (solid inflexible unit, not easily moved, resistant to manual pressure)	More than 5 mm
4	-	-	Banding (rope-like tissue that blanches with extension of scar, does not limit range of motion)-	-
5	-	-	Contracture (permanent shortening of scar producing deformity or distortion limits of motion)	-

**Table 2** Patient characteristics.

	Group I		Group II		<i>p</i> value
	No/mean	%/SD	No/mean	%/SD	
Age	36.88	14.49	43.0	11.76	0.28
Gender					
Male	12	37.5	4	50.0	0.69
Female	20	62.5	4	50.0	
Duration of the disease	20.75	9.08	25.0	6.41	0.22

The lesion criteria of the two groups had no significant difference ( $p > 0.05$ ).

and 20 females were included in group I, while group II included 4 males and 4 females. No significant difference was detected between the two groups regarding the age nor the sex ( $p > 0.05$ ) (Table 4).

## Discussion

The mitomycin C is an antibiotic produced by *Streptomyces caespitosus* that can alkylates, cross-link DNA and inhibit the DNA synthesis in the neoplastic cells. Also it can inhibit RNA and protein synthesis at high doses.<sup>9,10</sup> It may lead to DNA fragmentation in the late G1 and early S phase in the cell cycle as demonstrated in an in vivo and in vitro rat model.<sup>11</sup>

The mitomycin C can block the angiogenesis during the wound healing.<sup>12</sup> It may induce the apoptosis in the cultured corneal fibroblasts, and decrease the production of the transforming growth factor (TGF)- $\beta$ -induced protein in the corneal fibroblasts. The TGF- $\beta$  isoforms may play a central role in the wound healing and fibrosis. The addition of mitomycin C may lead to decrease of Bcl-xL mRNA expression

in the corneal fibroblasts. The Bcl-xL proteins may act as inhibitors of the mitochondrial apoptosis pathway.<sup>13</sup>

The mitomycin C can be administered intravenously in the treatment of gastric, pancreatic, bladder, breast, cervical, eye, liver and prostatic cancer. Also the mitomycin C may be used as an agent to inhibit the fibroblastic proliferation and activity. As it can lead to fibroblast arrest without sacrificing re-epithelialization. So it can be used successfully in the field of ophthalmology, paediatric and otorhinolaryngology.<sup>14</sup>

The laboratory and clinical studies on mitomycin C as a treatment option for keloids and HTS in dermatology and plastic surgery are few and far between.<sup>5</sup>

Simman et al. studied the use of mitomycin C at a concentration of 0.1 mg/mL for 5 min on the keloid fibroblasts in vitro, it can reduce the fibroblast density and the DNA synthesis after 3 weeks of the mitomycin use.<sup>9</sup>

Sewall et al. studied the effect of topical mitomycin C use on the full thickness skin wound contraction in hairless mice. The rate of wound contraction in the treated

**Table 3** Lesion characteristics between the two groups.

	Group I		Group II		<i>p</i> value
	No/mean	%/SD	No/mean	%/SD	
<i>Duration of the disease</i>	20.75	9.08	25.0	6.41	0.22
<i>Other affected sites</i>					
Present	16	50.0	4	50.0	1.0
Absent	16	50.0	4	50.0	
<i>Family history</i>					
Positive	20	62.5	4	50.0	0.69
Negative	12	37.5	4	50.0	
<i>Causative agent</i>					
Ear piecing	20	62.5	4	50.0	0.69
Surgical	12	37.5	4	50.0	
<i>Size changes</i>					
Enlarged	32	100	8	100	-
Not	0	0.0	0	0.0	
<i>Colour changes</i>					
Brown	8	25.0	0	0.0	0.08
Brown to dark	8	25.0	0	0.0	
Dark	8	25.0	4	50.0	
Pink	8	25.0	4	50.0	
<i>Pain</i>					
Itchy pain	12	37.5	4	50.0	0.31
Needle like pain	8	25.0	0	0.0	
Painless	12	37.5	4	50.0	

Both treatment group showed a significant improvement in the VSS score after treatment ( $p < 0.001$ ). Although the initial VSS did not differ between the study groups ( $p = 0.39$ ), the topical group showed marked reduction in VSS score when compared to the intra-lesional one ( $p = 0.002$ ).

**Table 4** Differences of initial and final VSS among each group of treatment.

	Group I		Group II		<i>Total</i>	
	<i>Mean</i>	$\pm$ SD	<i>Mean</i>	$\pm$ SD	<i>Mean</i>	$\pm$ SD
Initial VSS	10.63	1.13	11.0	0.93	0.39	
Final VSS	1.38	1.24	3.0	1.07	0.002	
<i>p</i> value	<0.001		<0.001			

The excellent patient satisfaction was 62.5% in group I, while good patient satisfaction was 37.5%. There was no excellent patient satisfaction in group II, while good patient satisfaction was 100%.

group was less than in the control group. Also, the treated group had a larger wound surface area after 1 month than in the control group, But the wound area in the control group contracted nine times more rapidly than in the treatment groups.<sup>15</sup>

Many authors may find the success of the short-term mitomycin C contact immediately after the keloid or hypertrophic scar excision, But the intralesional mitomycin C use is not been studied well.<sup>16</sup>

In 2012, there was the first trial to study the effect of intralesional mitomycin C use in the keloids and HTS treatment by Seo and Sung. They had negative results the reasons behind the negative results of intralesional mitomycin C should be examined.<sup>5</sup>

In this study, both groups showed a significant improvement in the VSS score when compared to the pre-treatment values ( $p < 0.001$ ). However, although the initial VSS score did not differ between the two groups ( $p = 0.39$ ), it was significantly improved in the topical group compared to the intra-lesional cases (1.38 vs. 3.0 –  $p = 0.002$ ) (Table 5).

In Stewart et al. study on 10 patients who had surgical excision of head and neck keloids followed by mitomycin C-soaked pledgets application for 4 min. It was effective in prevention of recurrence after 6–14 months, with 90% success rate.<sup>17</sup>

In Bailey et al. study on 10 patients, the application of mitomycin C to the base of shave-removed keloids could prevent its recurrence. The topical mitomycin C (1 mg/mL)

**Table 5** Comparison between topical and intra-lesional groups according to VSS and patient satisfaction.

	Group I		Group II		<i>p</i> value
	No	%	No	%	
<i>Patient satisfaction</i>					
Excellent	20	62.5	0	0.0	0.003
Good	12	37.5	8	100	

was put for 3 min. 8 of the 10 patients were satisfied with the treatment outcome while 2 patients were unsatisfied, with 80% satisfaction rate.<sup>18</sup>

The result of intralesional mitomycin C treatment was unsatisfied, as the patients had severe pain, severe erythema, blistering, necrosis and increased ulceration after intralesional mitomycin C therapy. But the topical application of mitomycin C would be promising in the auricular keloid treatment as VSS reduced from 10.11 down to 1.22.<sup>5</sup>

The topical application of mitomycin in the wound bed would reduce the scar formation rate, 3 (13%) of the 23 patients with mitomycin C treatment had recurrent keloids, while 11 (65%) of 17 patients had recurrent keloids without mitomycin C treatment ( $p=0.002$ ).<sup>19</sup>

The patients satisfaction would improve in the topical group ( $p=0.003$ ). Excellent outcomes were achieved in 20 cases (62.5%) in the topical group, while the remaining patients had good outcomes. In the intra-lesional group the all patients had good outcomes.

Talmi et al. studied the effect of mitomycin C application after the keloid excision. All patients had satisfied treatment outcome as the simple excision and closure had 45–100% recurrence rate.<sup>10</sup>

In Sanders et al. study, 15 patients with multiple keloids underwent postexcision application of topical mitomycin C (0.4 mg/mL) for 5 min postoperatively. After 6 months of follow-up, there were no difference in the recurrence rate between the mitomycin C-treated lesions and the untreated control lesions.<sup>20</sup>

The topical application of mitomycin c has been shown in numerous studies to be safe and literally without side effects, including long-term experience with its application in ophthalmologic surgery. The mitomycin C has been widely used for decades, is relatively inexpensive, and is readily available.<sup>10</sup>

## Conclusion

The topical and intra-lesional mitomycin C injection are effective methods in treatment of the auricular keloids, with better VSS scores and patient satisfaction in the topical administration.

## Ethical considerations

### Ethics approval and consent to participate

Local ethical committee approval and Informed consent had been obtained before the onset of this study.

## Consent for publication

Not applicable.

## Availability of data and material

Data are available on request.

## Funding

No external source of funding.

## Conflict of interests

No conflict of interest and nothing to disclose.

## References

- Jackson IT, Bhageshpur R, DiNick V, Khan A, Bhaloo S. Investigation of recurrence rates among earlobe keloids utilizing various postoperative therapeutic modalities. *Eur J Plast Surg.* 2001;24:88–95.
- Hao Y-H, Xing X-J, Zhao Z-G, Xie F, Hao T. A multimodal therapeutic approach improves the clinical outcome of auricular keloid patients. *Int J Dermatol.* 2019;58:745–9.
- Shaheen AA. Risk factors of keloids: a mini review. *Apoptosis.* 2017;2:5.
- Park SY, Lee G-H, Park JM, Jin S-G, Oh J-H. Clinical characteristics of auricular keloids treated with surgical excision. *Korean J Audiol.* 2012;16:134.
- Seo SH, Sung HW. Treatment of keloids and hypertrophic scars using topical and intralesional mitomycin C. *J Eur Acad Dermatol Venereol.* 2012;26:634–8.
- Dachlan I, Aryandono T, Wahyuningsih MSH, Soebono H, Wirohadidjojo YW. The effect of mitomycin-C in keloid fibroblast cultures. *J Med Sci (Berkala Ilmu Kedokteran).* 2016;48:167–74.
- Cummings J, Spanswick VJ, Smyth JF. Re-evaluation of the molecular pharmacology of mitomycin C. *Eur J Cancer.* 1995;31:1928–33.
- Sengupta A, Das A, Ghosh D, Dhara S, Ghosh S. The efficacy of local application of mitomycin C in reducing recurrence rate of keloid after surgery. *Bengal J Otolaryngol Head Neck Surg.* 2016;24:117–21.
- Simman R, Alani H, Williams F. Effect of mitomycin C on keloid fibroblasts: an in vitro study. *Ann Plast Surg.* 2003;50:71–6.
- Talmi YP, Orenstein A, Wolf M, Kronenberg J. Use of mitomycin C for treatment of keloid: a preliminary report. *Otolaryngol-Head Neck Surg.* 2005;132:598–601.

11. Ribeiro FdAQ, Guaraldo L, Borges JdP, Zacchi FFS, Eckley CA. Clinical and histological healing of surgical wounds treated with mitomycin C. *Laryngoscope*. 2004;114:148–52.
12. Hardillo J, Vanclooster C, Delaere PR. An investigation of airway wound healing using a novel in vivo model. *Laryngoscope*. 2001;111:1174–82.
13. Kim SCT, Lee HK, Cho YJ, Kim EK. Mitomycin C induces apoptosis in cultured corneal fibroblasts derived from type II granular corneal dystrophy corneas. *Mol Vis*. 2008;14:1222.
14. Xi-Qiao W, Ying-Kai L, Chun Q, Shu-Liang L. A review of the effectiveness of antimitotic drug injections for hypertrophic scars and keloids. *Ann Plast Surg*. 2009;63:688–92.
15. Sewall GK, Robertson KM, Connor NP, Heisey DM, Hartig GK. Effect of topical mitomycin on skin wound contraction. *Arch Facial Plast Surg*. 2003;5:59–62.
16. Ledon JA, Savas J, Franca K, Chacon A, Nouri K. Intralesional treatment for keloids and hypertrophic scars: a review. *Dermatol Surg*. 2013;39:1745–57.
17. Stewart CE IV, John Y. Kim Application of mitomycin-C for head and neck keloids. *Otolaryngol-Head Neck Surg*. 2006;135:946–50.
18. Bailey JNR, Waite AE, Clayton WJ, Rustin MHA. Application of topical mitomycin C to the base of shave-removed keloid scars to prevent their recurrence. *Br J Dermatol*. 2007;156:682–6.
19. Sanni A, Ikponmwosa S, Golio D, Tehrani K. The use of mitomycin C and keloid scar recurrence. *Plast Reconstr Surg*. 2010;126:3.
20. Sanders KW, Gage-White L, Stucker FJ. Topical mitomycin C in the prevention of keloid scar recurrence. *Arch Facial Plast Surg*. 2005;7:172–5.